

AOA appliances, etc.

In This Issue:

- Distal Jets Refined
- Past Mini-screw Distalization Methods
- A Better Mini-screw Insertion Site
- Horseshoe Jets

In this issue of AOAppliances, in a break from our customary format of offering two articles, we are offering a single extended review of fixed methods of molar distalization. The growing popularity of temporary anchorage devices (TAD) in many ways can be traced to clinicians like Dr. Jay Bowman. Jay has authored numerous papers and participated in many panels on the subject of TAD's and their usefulness in the orthodontic arena. His pioneering work in methods of distalizing molars combined with skeletal anchorage offers our readers solid clinical options and concepts.

AOA's experience in fabricating the various versions and modifications of distalizing appliances that may be used with TAD anchorage and the styles of TAD's on the market, including Ormco's remarkable Vector TASTM system, combines to offer our customers quick design reviews and technical support. Just check with our Tech Support Department for information.

We look forward to seeing you in Denver at the Ormco/AOA Booth, #500.



David Alieese
President,
AOA Laboratory



S. Jay Bowman, D.M.D., M.S.D.

Distal Jets Refined: Bowman Modification and Horseshoe Jet

S. Jay Bowman, D.M.D., M.S.D.

For something to endure, it must be unique. Dr. Ferdinand Porsche

Maxillary molar distalization has become a popular adjunct for Class II correction. Numerous "gadgets" have been introduced over the years, all designed to push maxillary molars back into a Class I relationship. Despite their popularity, many methods have some associated drawbacks such as anchorage loss or dependence upon unpredictable patient compliance.

Since 1996, one of the best-documented and most reliable devices for molar distalization has been the Distal Jet.^{1,4} Anchorage loss has been significantly diminished with the introduction of a new refinement, the so-called Bowman Modification [Fig.1].⁵ The Bowman Modification features a rigid tracking wire rather than the original "tube and piston" construction. Conversion of this device to a modified Nance holding arch (after distalization) has been streamlined. All hex screws are simply locked, the premolar supporting wires are cut, and the coil springs are left in place [Fig 1,2,3].^{1,5,6}

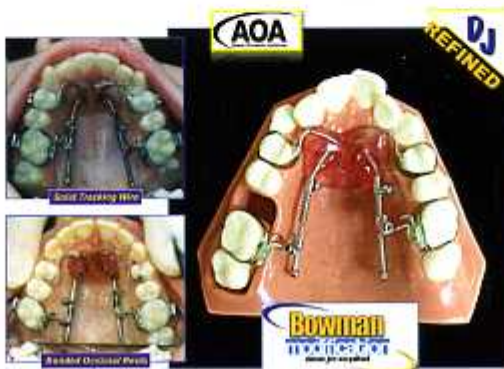

Figure 1

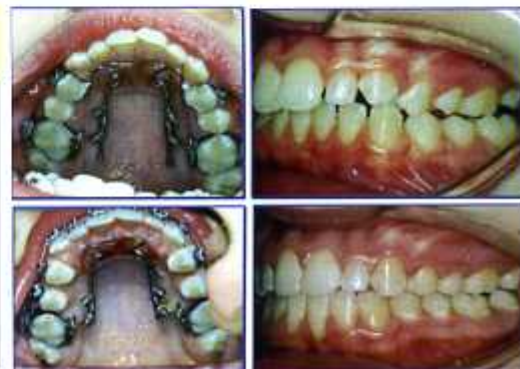

Figure 2

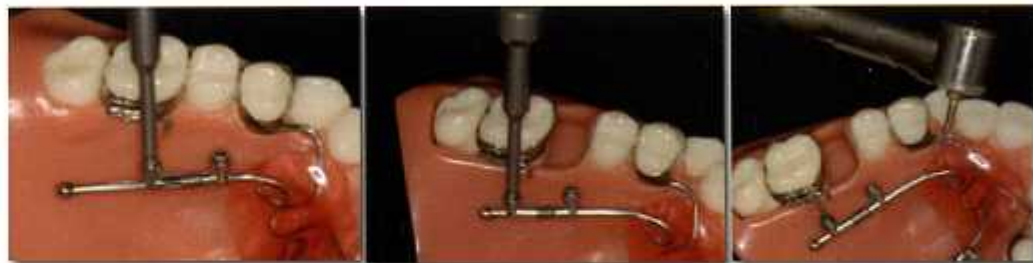

Figure 3

Past Mini-screw Distalization Methods

Reducing anchorage loss during distalization has lead to the logical incorporation of mini-screw anchorage into these type of biomechanics.^{5,9} Most initial attempts have involved the placement of some type of implant in

CENTRALIZED
COMMUNICATION CENTER
800-262-5221
INTERNATIONAL #262-886-1050

AOA Wisconsin
13931 Spring Street
Sturtevant, WI 53177
Fax 262-886-6879

AOA Connecticut
6 Niblick Road
Enfield, CT 06082
Fax 860-741-7655

the anterior palate.^{7,15} Unfortunately, when mini-screws are placed in this area, a painful incisive foramen injection is often necessary, the bone quality in this region is questionable for adolescents, intermittent forces are produced by the tongue, and food debris accumulation may contribute to premature implant failure. In addition, implants have often been "keyed to" the construction of the distalizing appliance (e.g., inserted through the acrylic button or attached to the framework using light-cured adhesives) in an attempt to enhance unpredictable dental or palatal vault anchorage. If mini-screws are integral to the construction of an appliance, there are several drawbacks: 1) Soft tissue inflammation is possible under the acrylic or framework; 2) Implants cannot be easily tested to check for premature mobility or failure; 3) If a screw fails, the entire appliance may need to be removed and/or re-fabricated; especially if a replacement screw is moved to a new location.

A Better Mini-screw Insertion Site

Rather than place mini-screws in the anterior palate or adjacent to the palatal suture, a more favorable mini-screw insertion point is located on the lingual side of the maxillary alveolus; between the maxillary first molars and second premolars (Fig. 4). Poggio *et al.*¹⁶ reported this area had the largest amount of interradicular bone on either side of the maxillary alveolus (Fig. 4). When a mini-screw is inserted at an angle (30-45°) to the sloping surface of the alveolus, sufficient thickness of the cortical bone (from 1.7 ± 0.5 mm to 2.2 ± 0.4 mm for adults) is available.¹⁷ Sonis¹⁸ also found a similar amount of cortical bone (about 1.7 mm) for adolescents; an age group of patients that would most often benefit from this type of predictable Class II distalization.

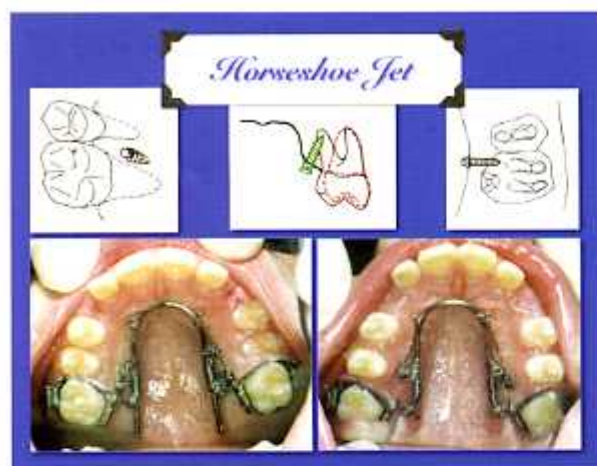


Figure 4

Horseshoe Jet

The Horseshoe Jet was designed to completely rely upon the palatal mini-screws for anchorage (Fig. 5,6).^{5,7,11} This eliminates questionable dental or palatal vault anchorage and any attendant anchorage loss. This design still benefits from forces that are applied through a couple, closer to the center of resistance of the molars; a hallmark of the Distal Jet.^{1,3,5} As a consequence there is dramatically less adverse molar tipping compared to other appliances.^{1,3,5} When mini-screws are inserted on the lingual alveolus^{19,20} as with the Horseshoe Jet,^{5,6,11,21} there is more favorable bone, more attached gingiva, and less likelihood of touching a root at this palatal insertion point; resulting in a lower incidence of mini-screw failure compared to other locations.

Step-by-Step: Horseshoe Jet

- 1) Fit bands on maxillary first molars and take an impression
- 2) Ship models with the bands to AOA for Horseshoe Jet fabrication
- 3) Apply topical anesthetic^{5,21,22} (e.g., 20% TAC alternate) and infiltrate anesthetic *prn*
- 4) Bend the double-back bayonet wire inserted in the molar lingual sheath to rotate the molars *prn*
- 5) Seat, but do not cement the Horseshoe Jet

Another feature of this lingual insertion site is that the palatal root of the maxillary second premolar is positioned buccally, away from the mini-screw while the palatal root of the first molar is oriented posteriorly. Substantial space is available for screw insertion between the roots of these two teeth and may result in: 1) Less potential for iatrogenic damage when inserting screws. 2) A mini-screw can be positioned distally, closer to the palatal root, providing more distance for premolar retraction before a root could encounter a mini-screw. 3) The second premolar root is likely to miss the lingually-positioned mini-screw during subsequent retraction of the other teeth anyway (Fig. 4,5). In other words, the mini-screws may not need to be moved to a different location after distalization and when the remaining teeth are retracted.

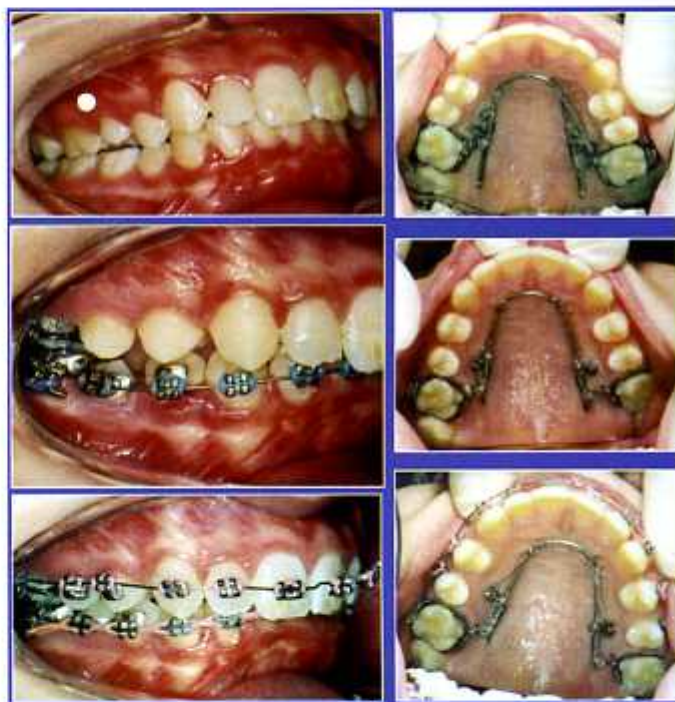

Figure 5

- 6) Impress a periodontal probe into the lingual tissues to mark the locations for mini-screw insertion (usually 5 mm from the gingival margin) so as to avoid interference with the Horseshoe Jet framework
- 7) Remove the Horseshoe Jet
- 8) Directly insert the mini-screws with a hand driver (straight or latch/contraangle) at a 30-45° angle to the lingual alveolus
- 9) Tie stainless steel ligatures around the head of each mini-screw
- 10) Seat and cement the Horseshoe Jet
- 11) Tie the ligatures tightly from the mini-screws to each hook on the tracking wire
- 12) Unlock the distal hex screw (1/4 turn counter-clockwise) to permit molar distalization
- 13) Push the activation collar (mesial hex screw) distally to compress the coil spring. Then lock only the mesial hex screws to hold the spring compression. Re-activate every 4-6 weeks *prn*
- 14) After distalization is complete, lock the distal hex screws to stop the process. This converts the Horseshoe Jet into a mini-screw based holding arch to support retraction of the remaining teeth without anchorage loss

The typical acrylic Nance button or bulky framework featured in many distalizing devices is absolutely unnecessary with the Horseshoe Jet. Anchorage is derived strictly from the mini-screws as they are tied to hooks on the horseshoe-shaped tracking wire using stainless steel ligature wire (Fig. 5,6). In addition, all hex screws can be loosened to adjust the mesial/distal position of the tracking wire as desired during treatment. Since the integrity of the mini-screws are completely independent from the appliance construction, the stability of each one can be easily tested and, if necessary, a failed screw can be easily removed and replaced in any number of alternate locations (even in the anterior palate) without having to fabricate a new appliance.^{5,6,11,21}

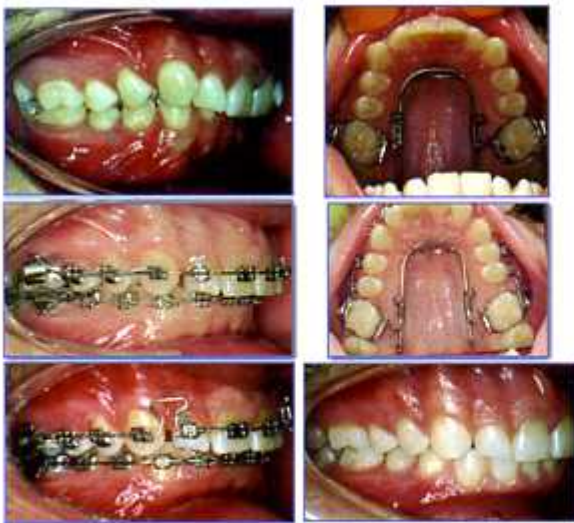

Figure 6

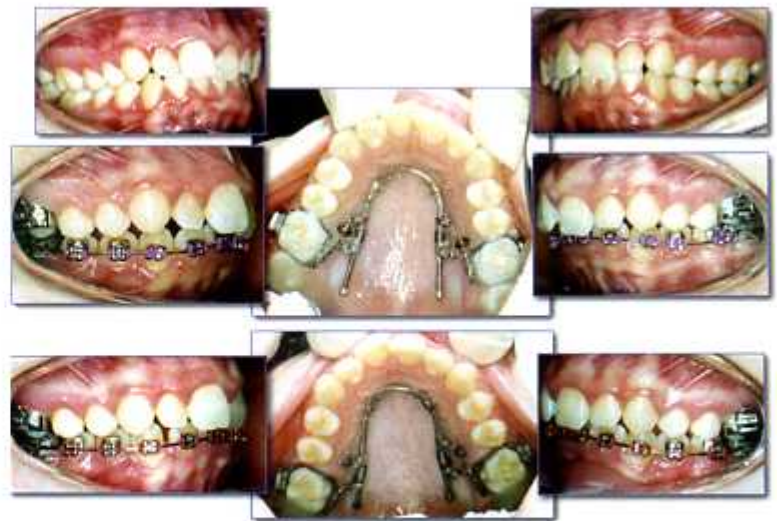

Figure 7

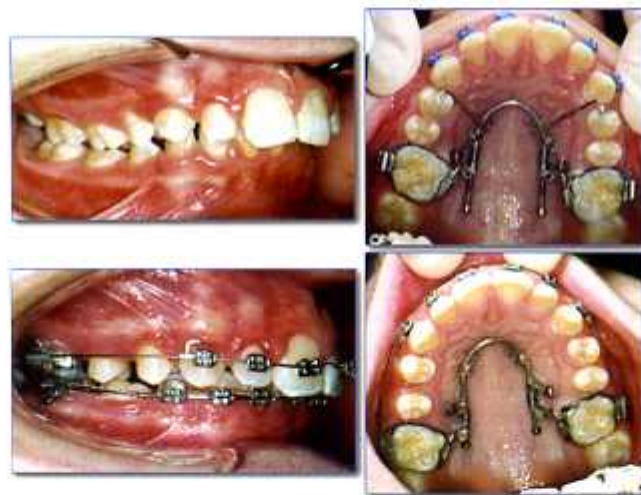

Figure 8

At the completion of distalization, the distal hex screw is locked onto the tracking wire to stop the process and (Fig. 5-8) the open coil spring is simply left in place. The Horseshoe Jet then serves as indirect anchorage to resist mesial movement of the molars during retraction of the remaining maxillary teeth. In this manner, mini-screw anchorage is available during both molar distalization and subsequent retraction of the remaining maxillary teeth: **one mini-screw based Horseshoe Jet serves two purposes.**

Bowman Modification and Horseshoe Jet, U.S. Patent # US 2003/0091952 A1 6/21/05

